

ARRITMIAS I

Dr. Jorge González Zuelgaray


Jefe de los Servicios de Electrofisiología

Sanatorios de la Trinidad San Isidro y Ramos Mejía

Director de la Carrera de Especialistas en Arritmias y
Electrofisiología Clínica, Universidad de Buenos Aires

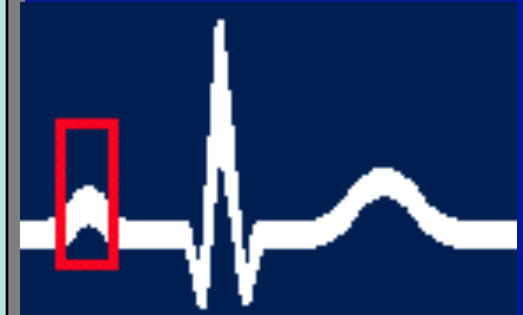
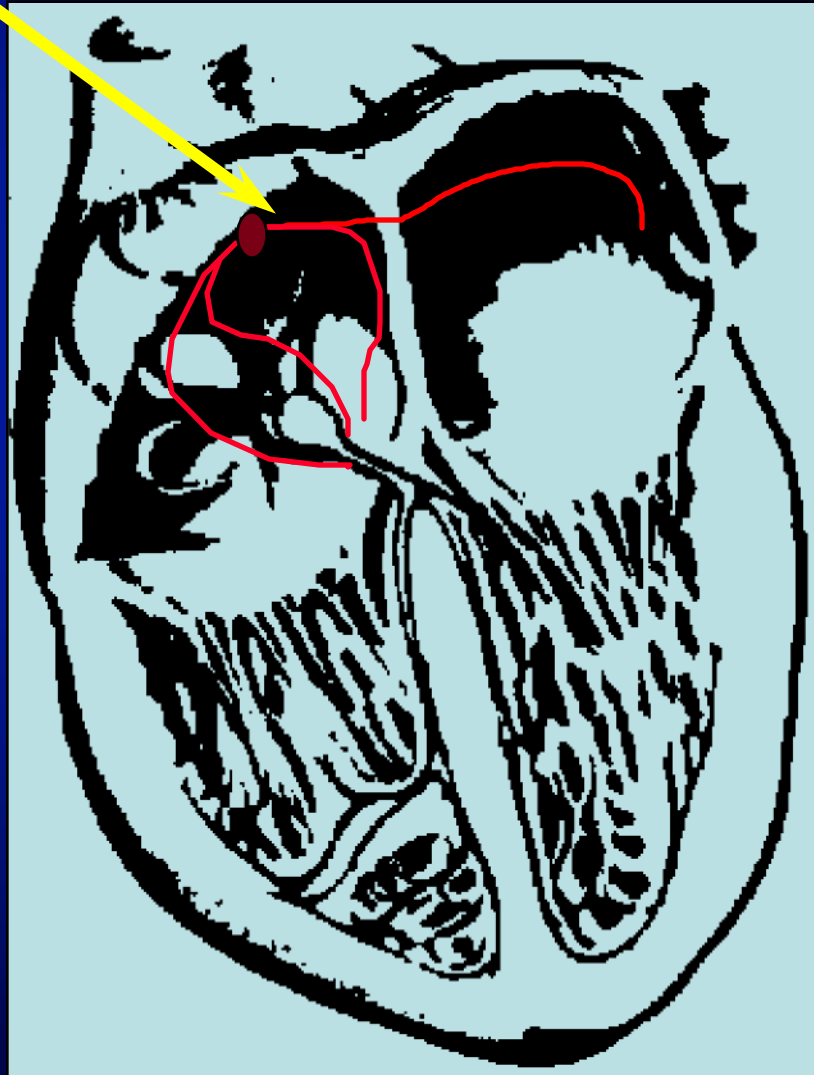
BLOQUEOS AV

Bloqueo AV de primer grado

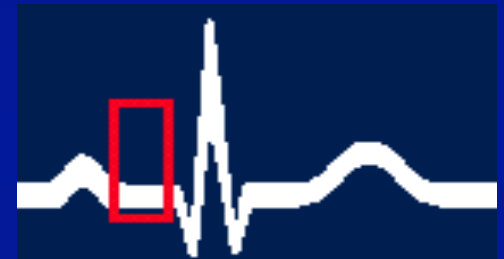
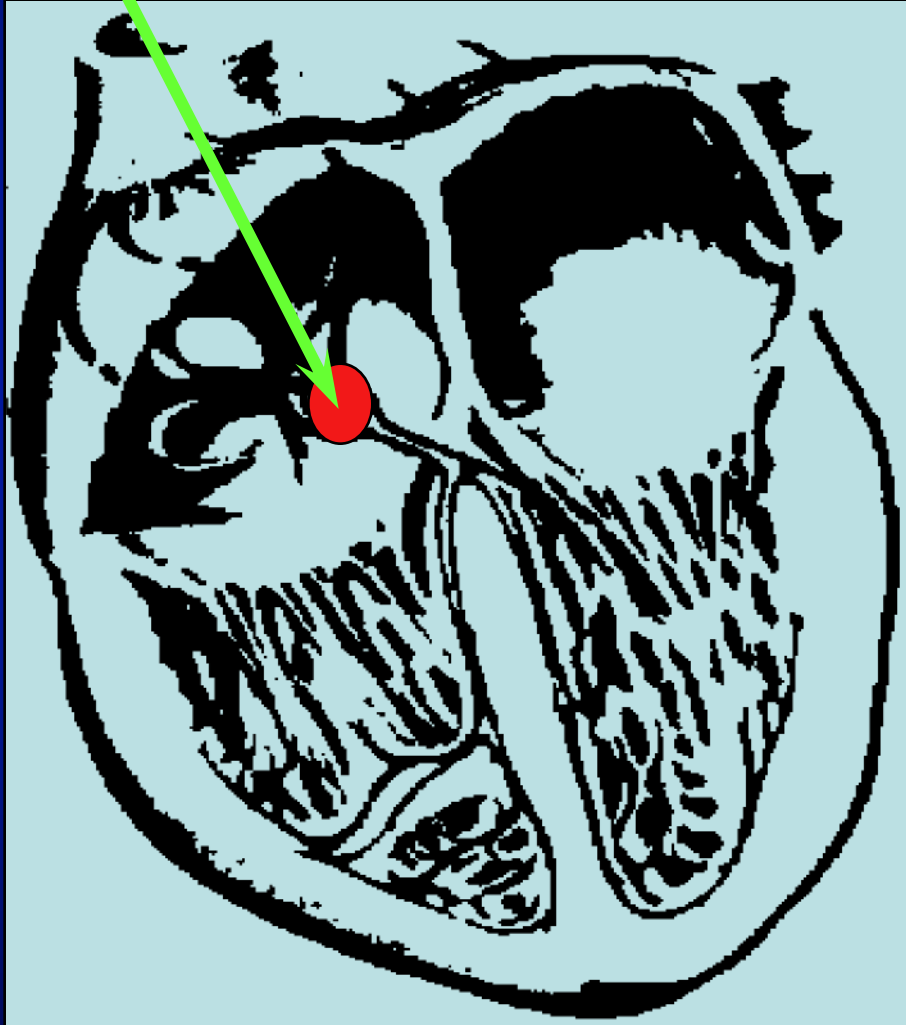


PR > 0,20 seg.

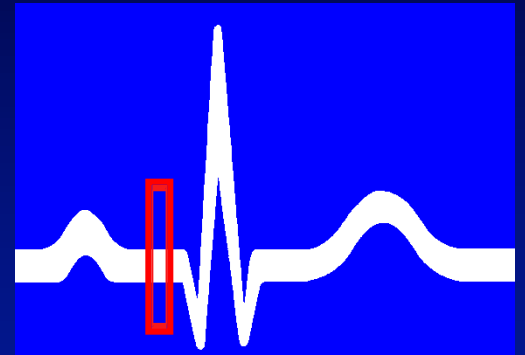
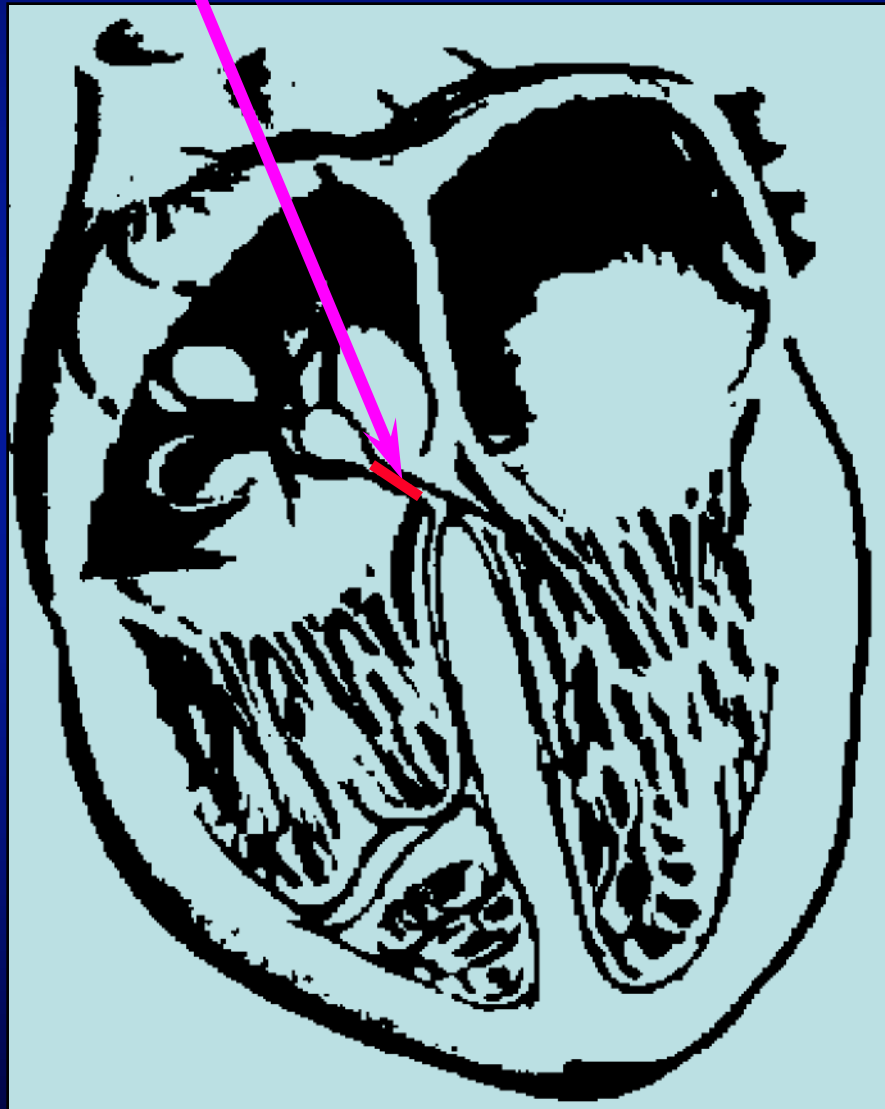
Nódulo sinusal y aurículas



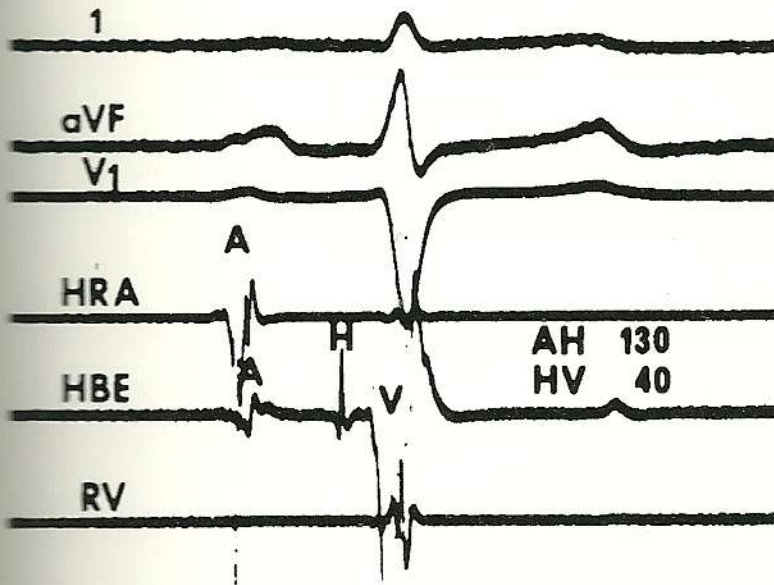
Nódulo A-V



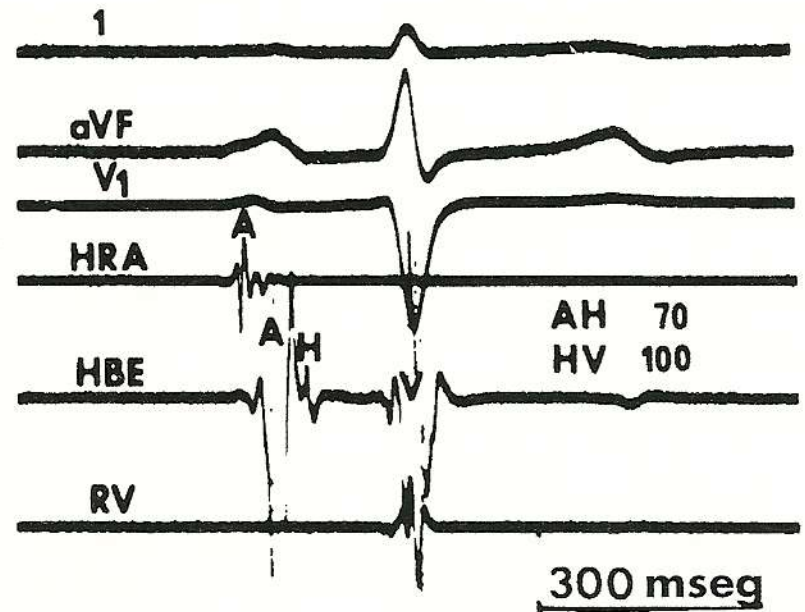
Haz de His



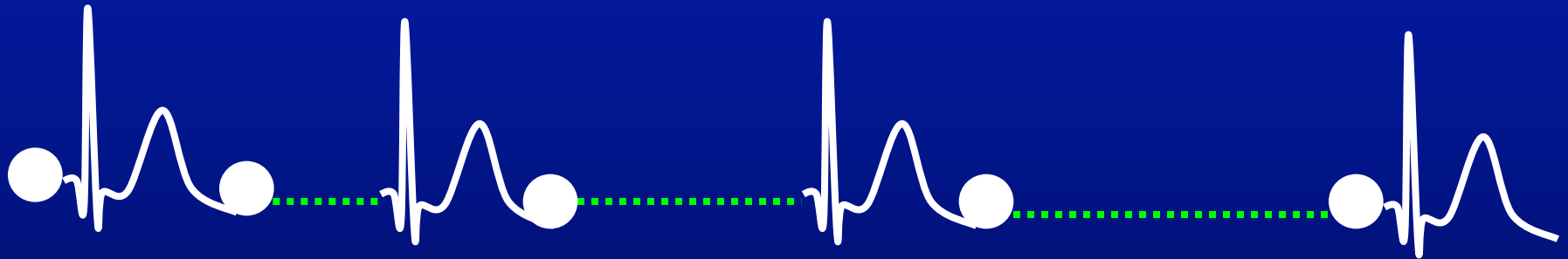
DISTAL

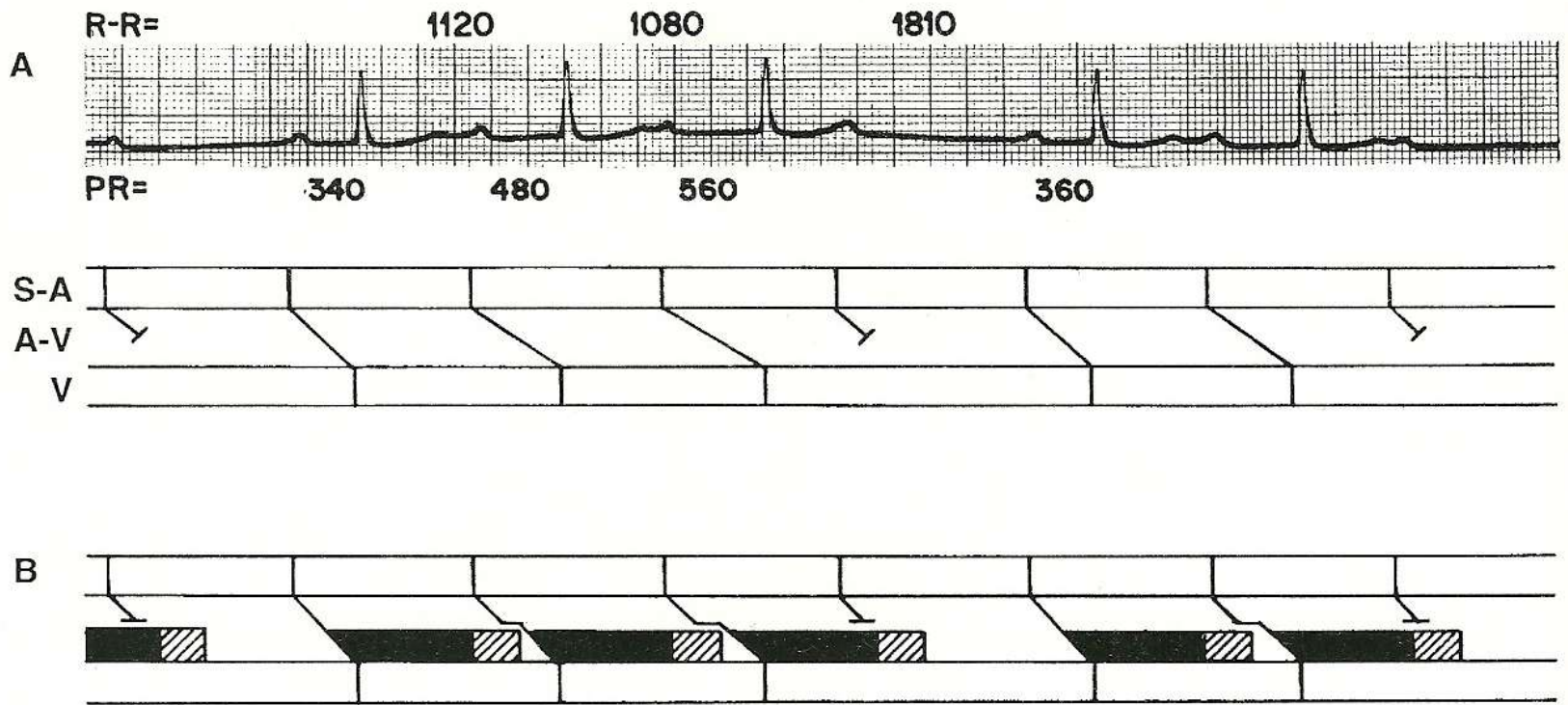


PROXIMAL

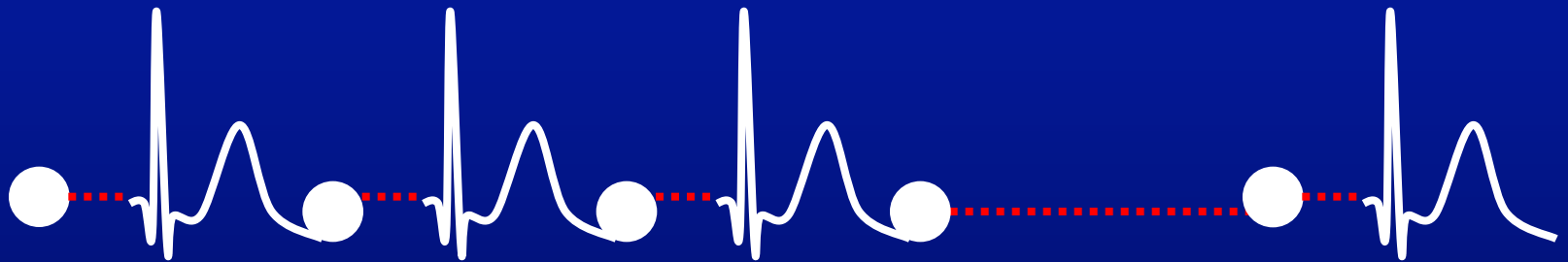


Bloqueo AV 2do. Grado (Wenckebach)

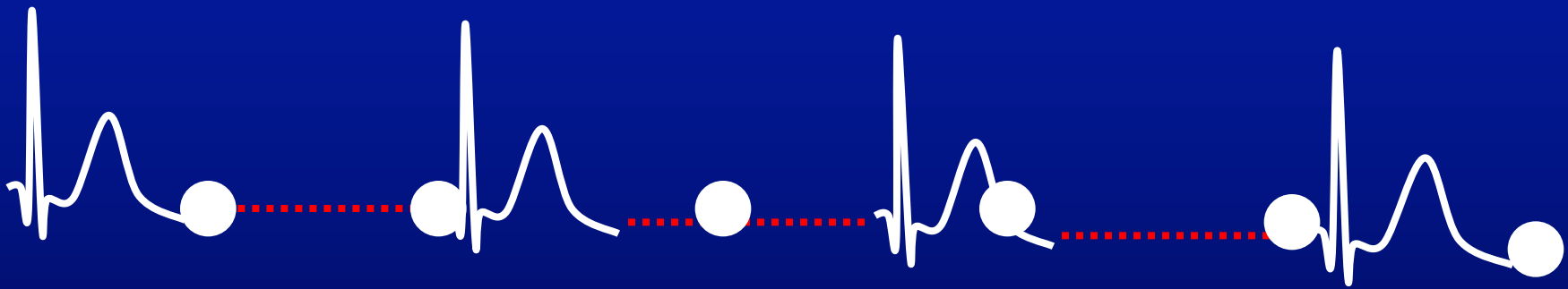





Bloqueo AV 2do. Grado (Mobitz)

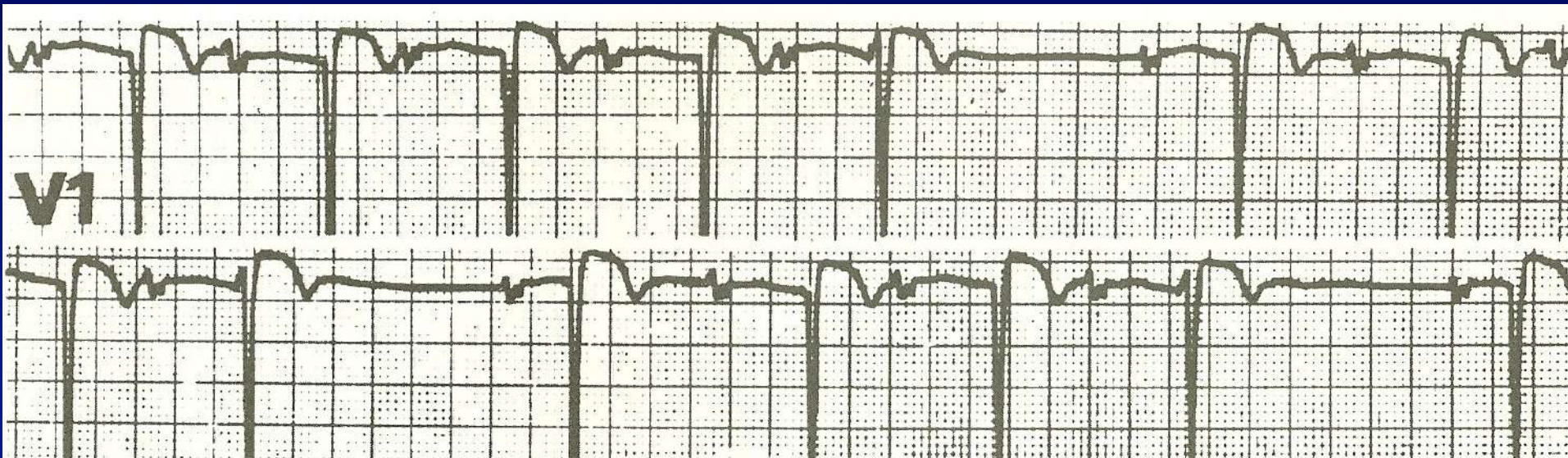


Bloqueo AV 3er. Grado (bloqueo AV completo)

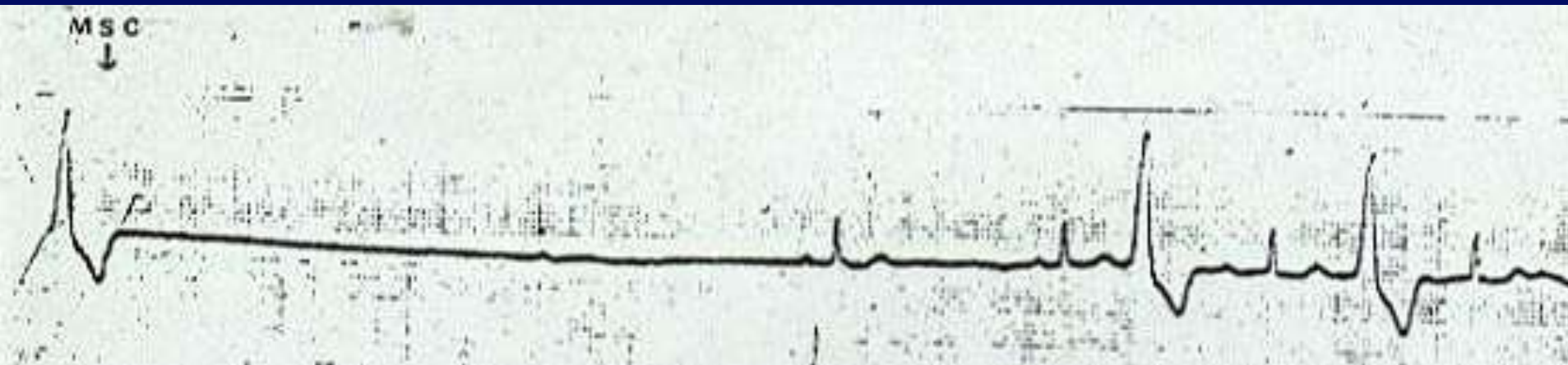



Ejercitación

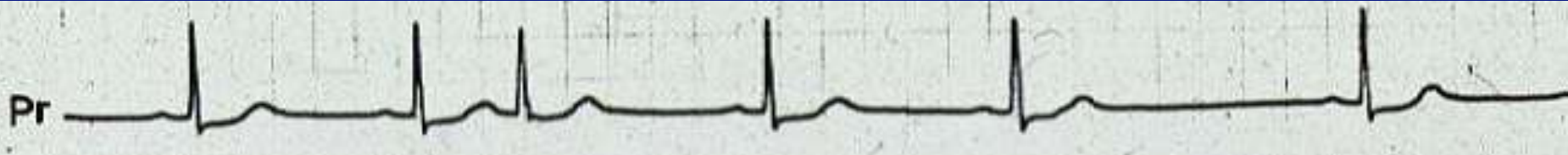


- 1) Wenckebach AV
- 2) Disociación AV
- 3) Secuela de necrosis anterior o anteroseptal
- 4) Extrasistolia auricular bloqueada



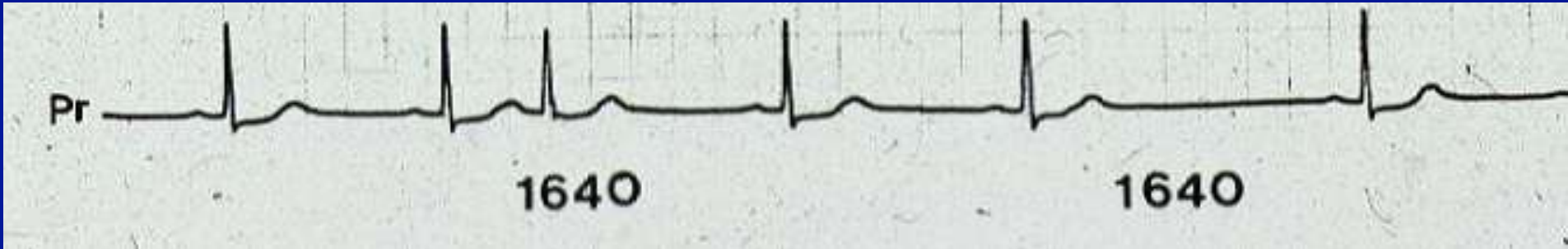
Varón, 60 años con síncope. DII larga, MSC y pausa de 7 segundos.

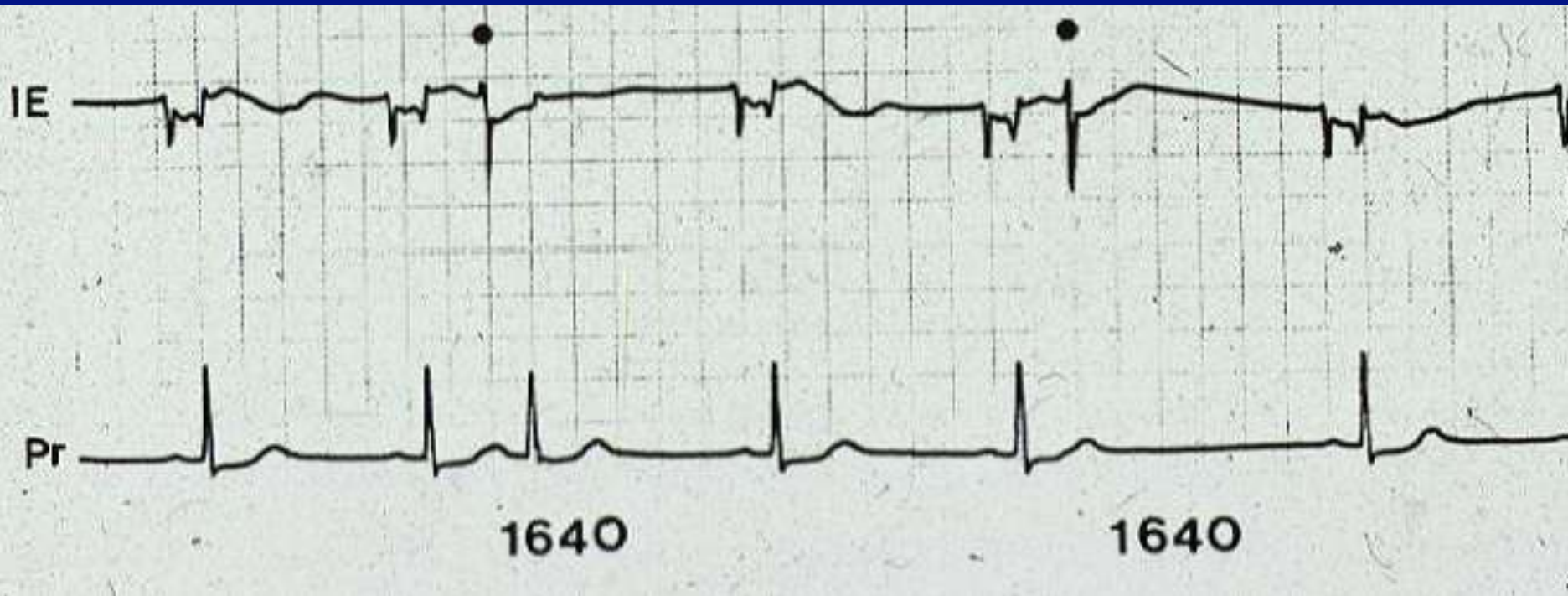
- 1) Indico marcapasos
- 2) Indico un cardiodesfibrilador implantable
- 3) Trato la extrasistolia con antiarrítmicos



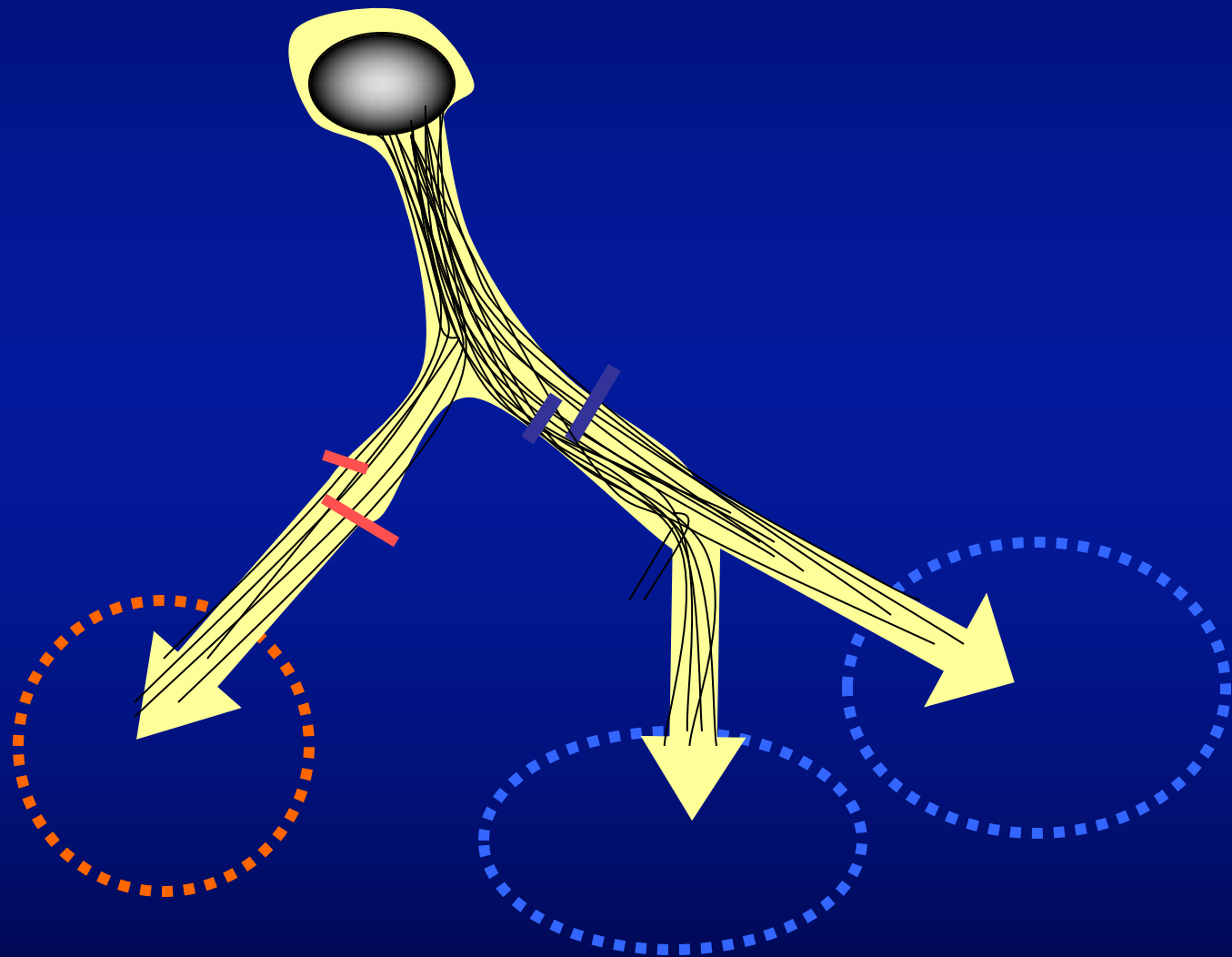
Mujer, 37 años. Palpitaciones

- 1) Extrasístole supraventricular
- 2) Enfermedad del nódulo sinusal
- 3) 1 y 2 son correctas





BLOQUEOS DE RAMA



BLOQUEO DE RAMA DERECHA



BLOQUEO DE RAMA DERECHA

- $QRS \geq 0,12$ seg
- $R' \text{ en } V1 > R$ (rsR' o rSR')
- S en I y V5-V6

I

II

III

aVR

aVL

aVF

V₁

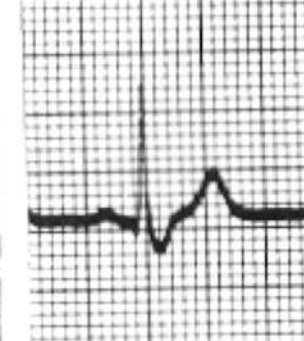
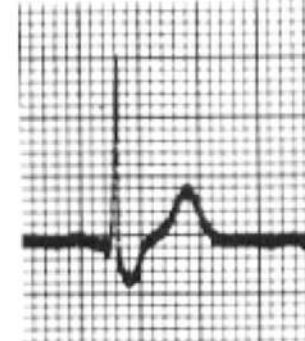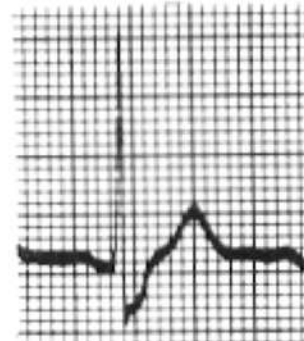
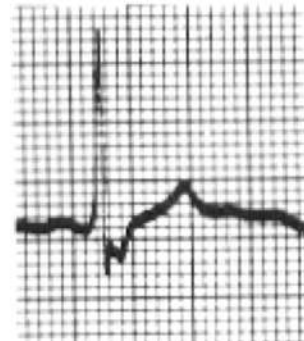
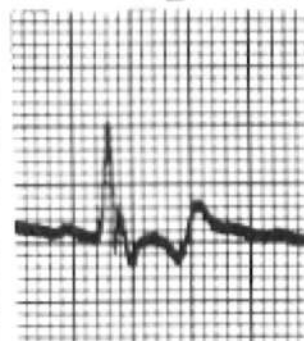
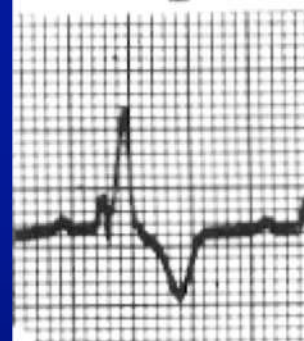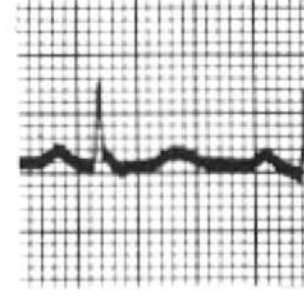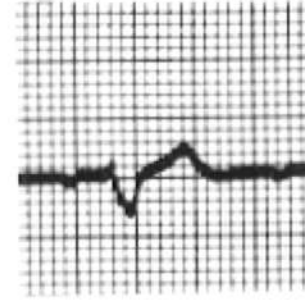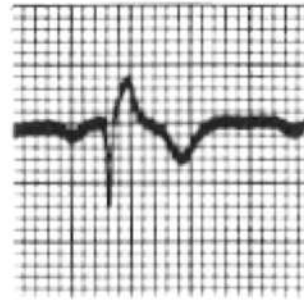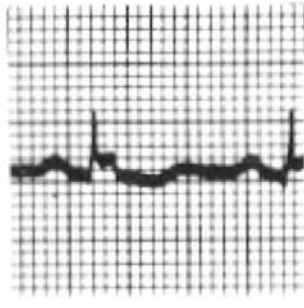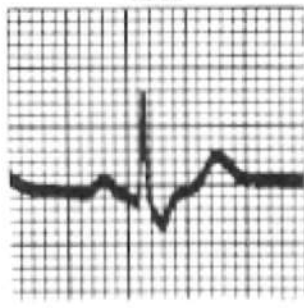
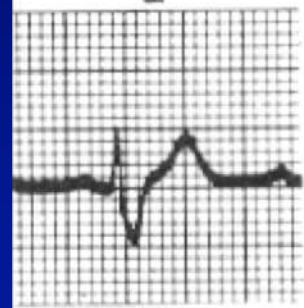V₂

V₃

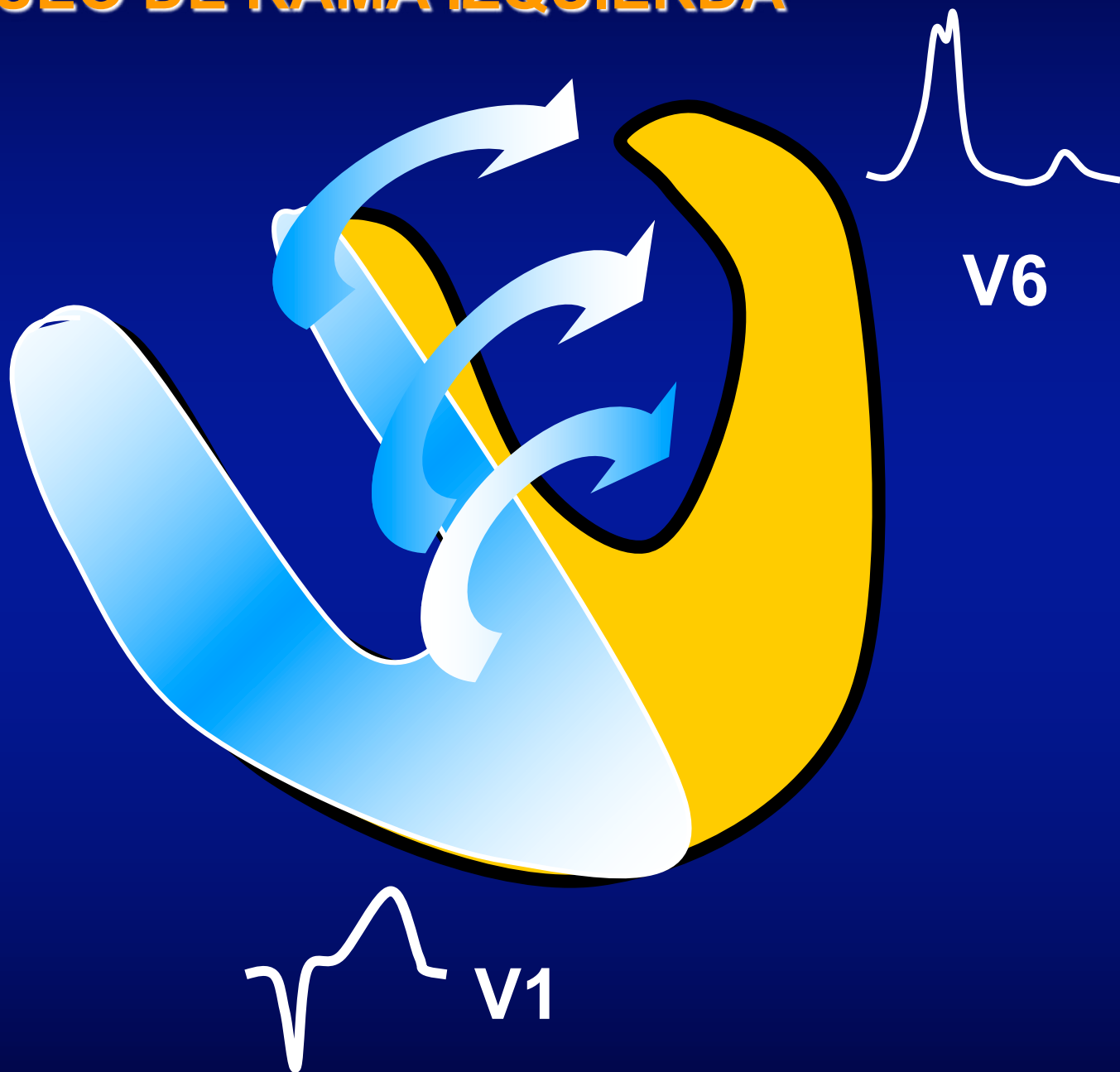
V₄

V₅

V₆

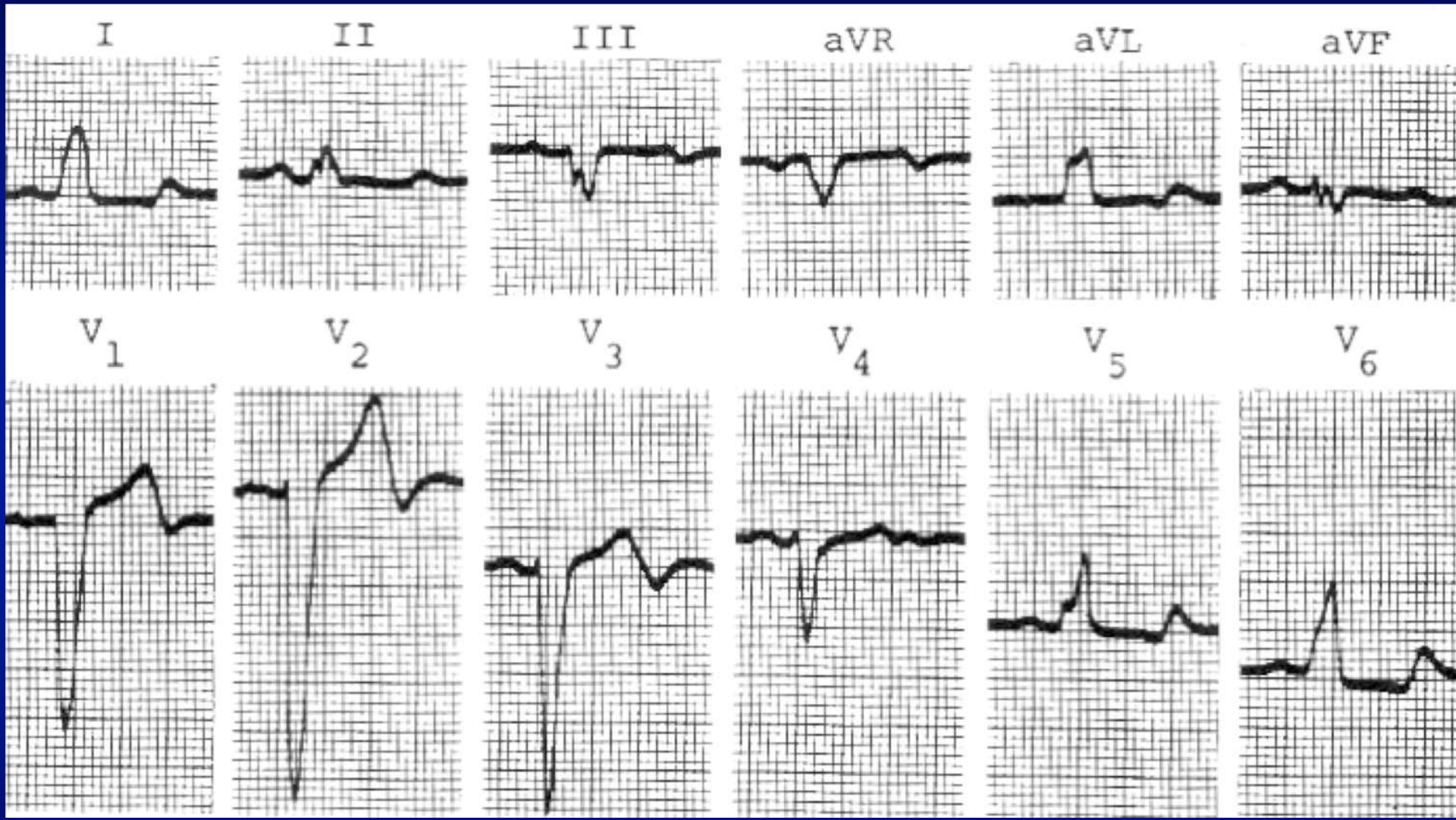


BLOQUEO DE RAMA IZQUIERDA




BLOQUEO DE RAMA IZQUIERDA

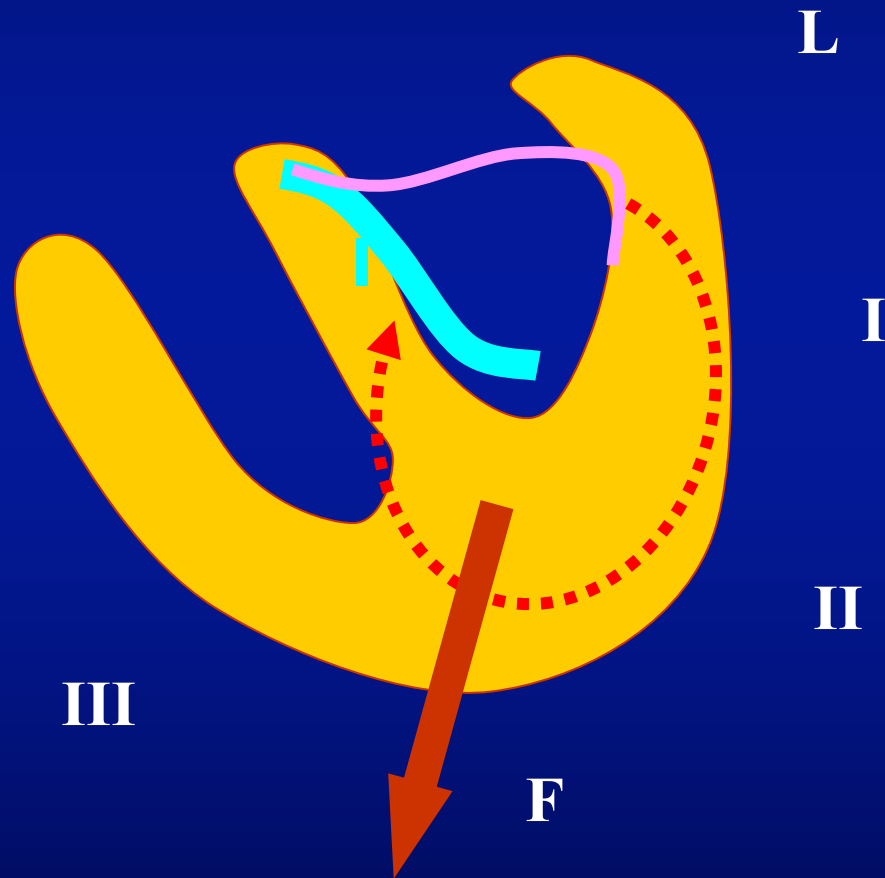
- **QRS \geq 0,12 seg**
- **Melladuras de R en I y V5-V6**
- **Ausencia de Q en I y V5-V6**
- **ST y T oponentes**



Hemibloqueos



HEMIBLOQUEO POSTERIOR (posteroinferior)



Lead I

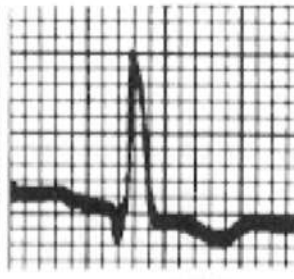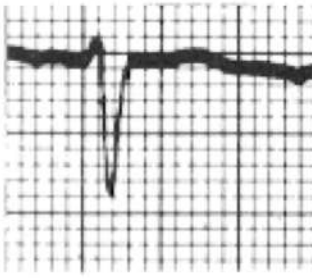
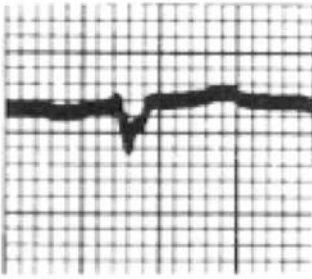
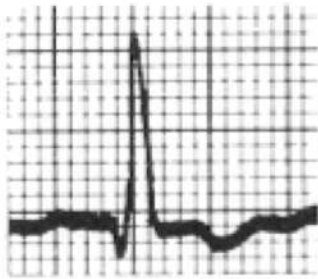
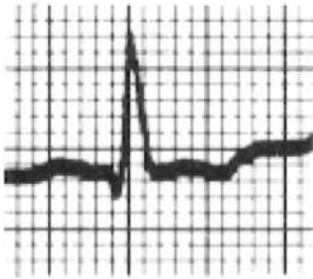
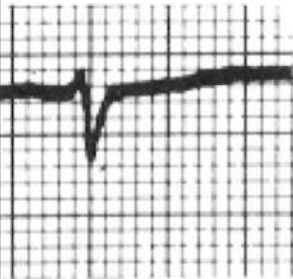
Lead II

Lead III

aVR

aVL

aVF



V₁

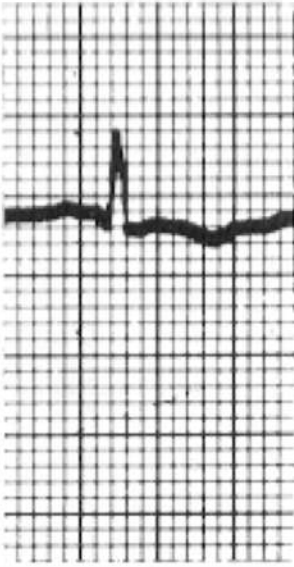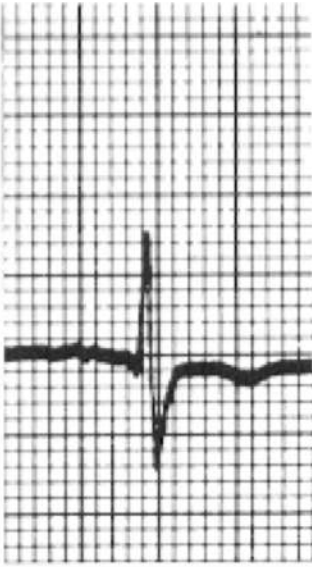
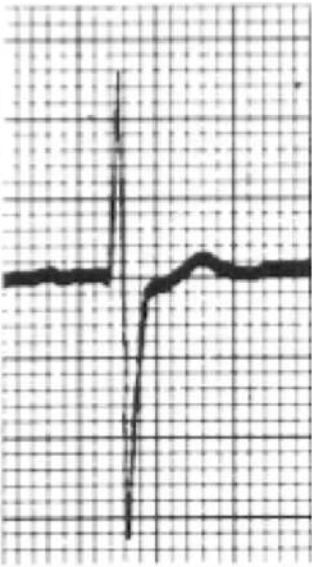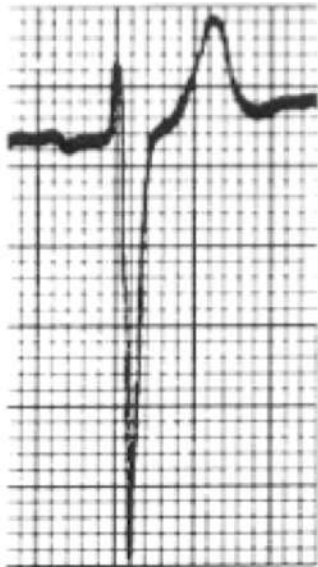
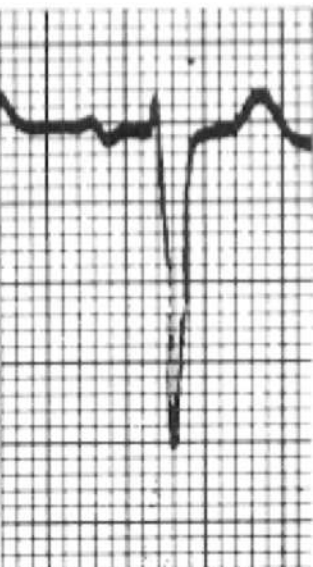
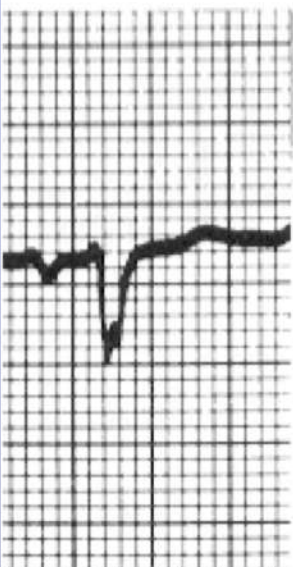V₂

V₃

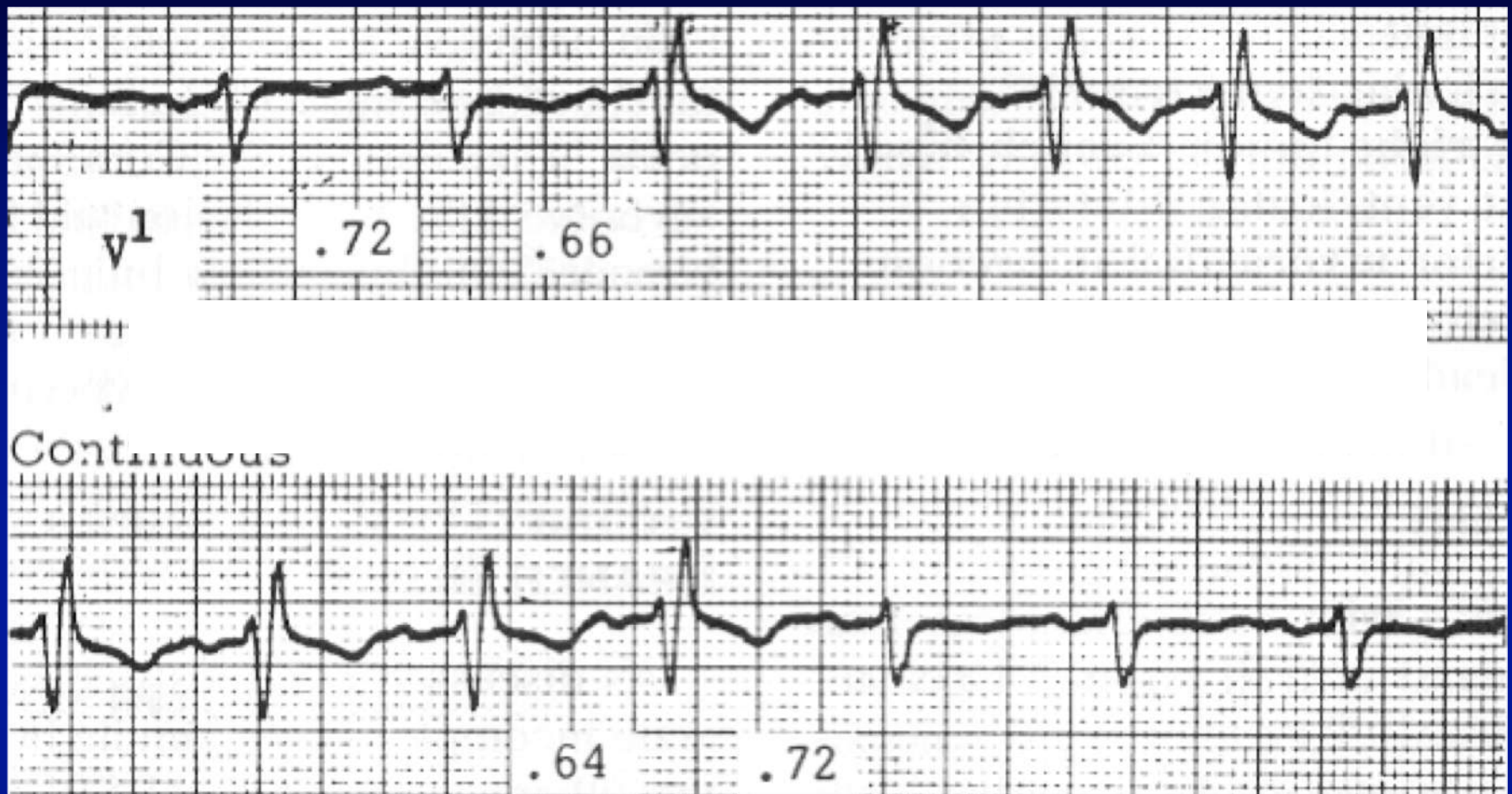
V₄

V₅

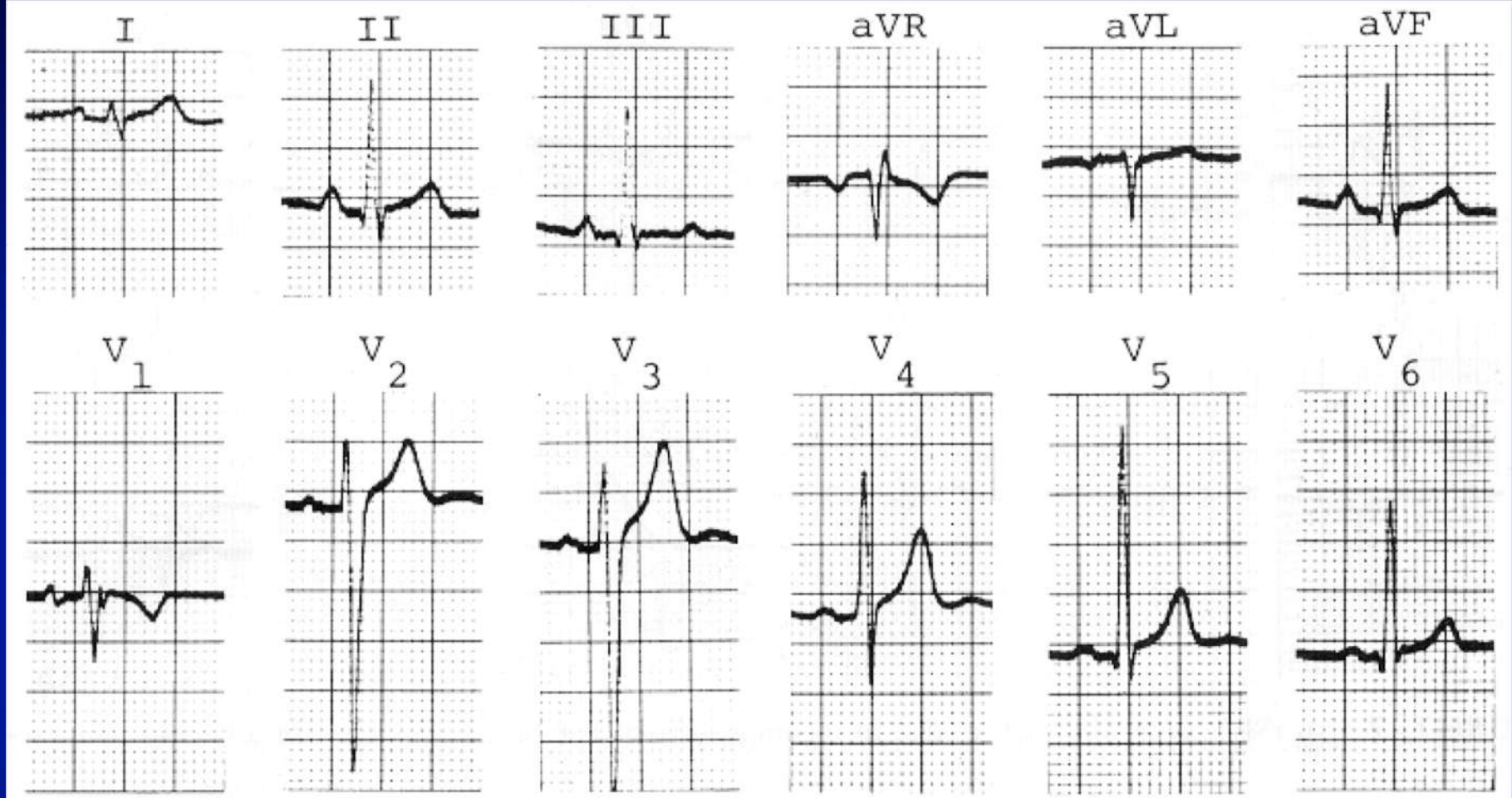
V₆



EJERCITACIÓN

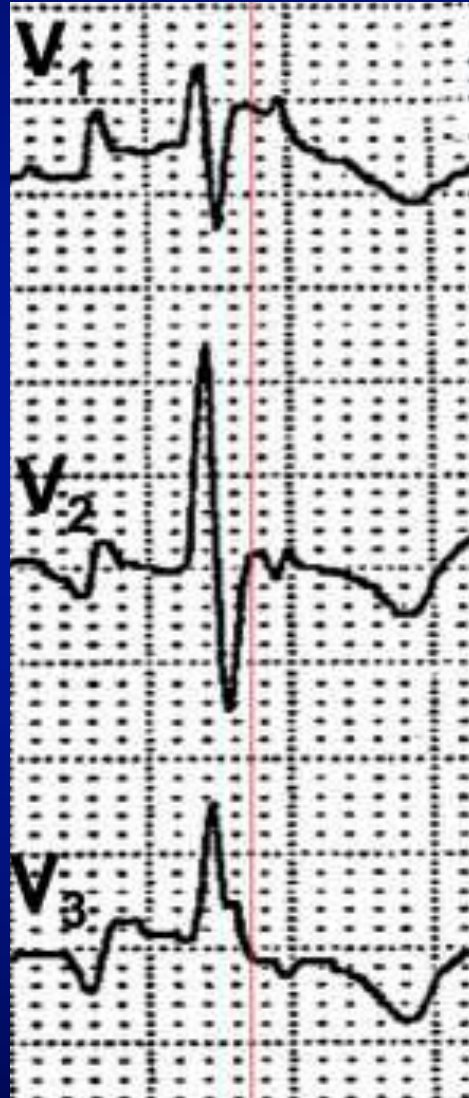


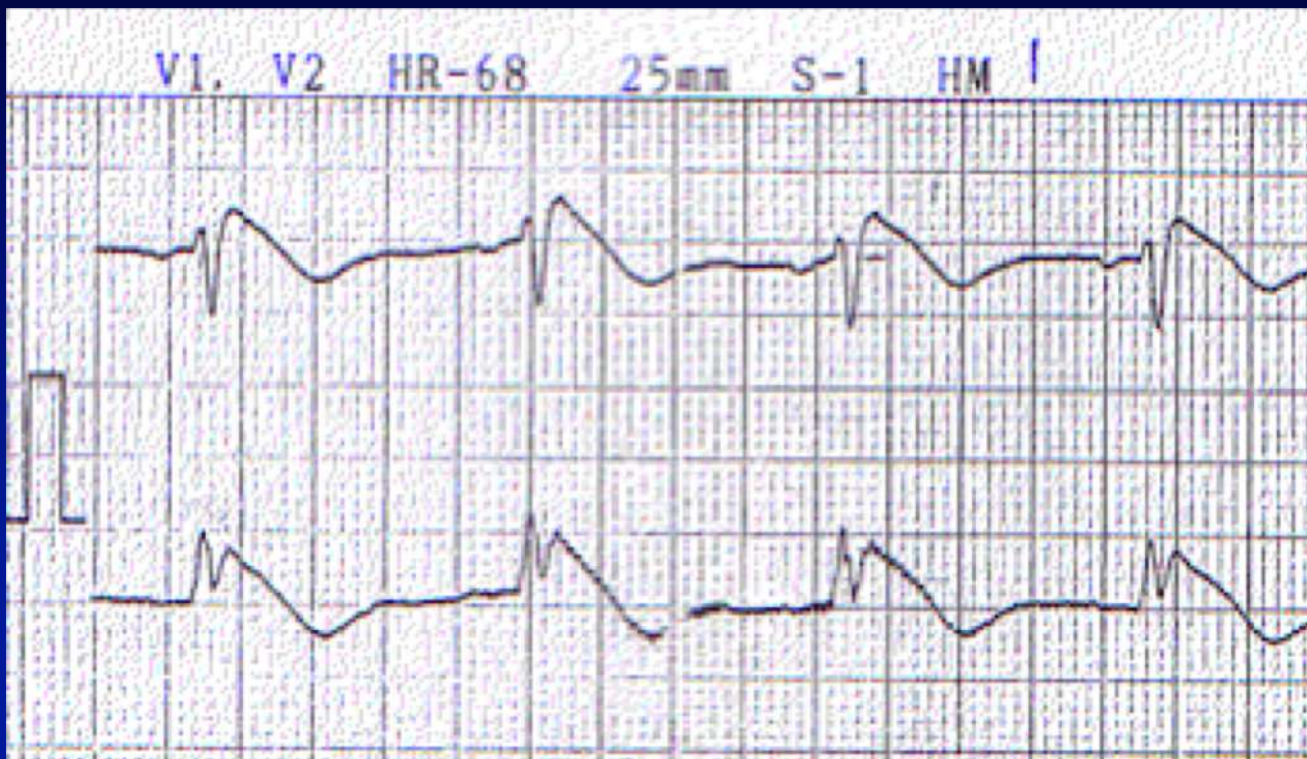
- 1) BRI intermitente no dependiente de la frecuencia
- 2) BRI intermitente taquicárdico-dependiente
- 3) BRD intermitente no dependiente de la frecuencia
- 4) BRD intermitente taquicárdico-dependiente



- 1) Bloqueo incompleto de rama derecha
- 2) Variante normal
- 3) Onda épsilon

Onda épsilon





Varón de 32 años con síncope e historia familiar de MS. Derivaciones V1 y V2.

- 1) Onda delta
- 2) Patrón de Brugada
- 3) Repolarización precoz

1

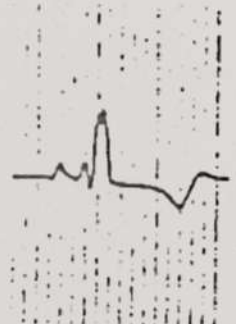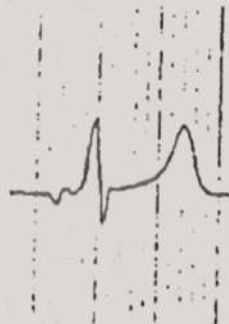

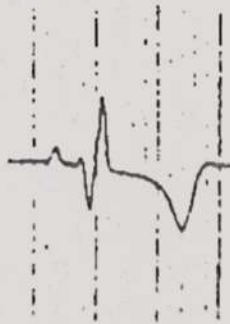
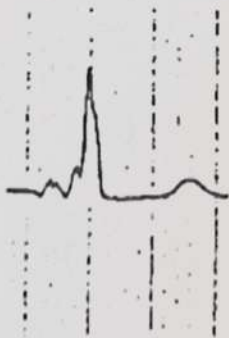
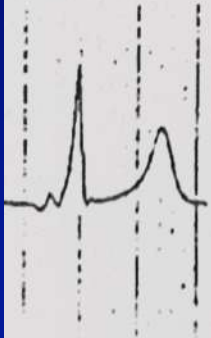
2

3

aVR

aVL

aVF



V1

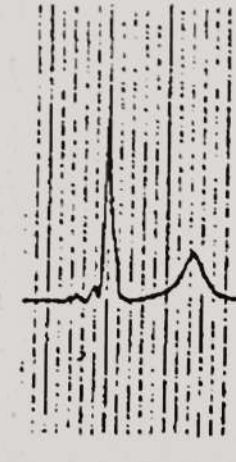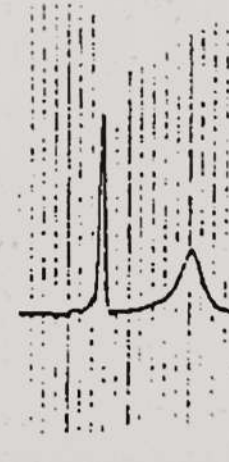
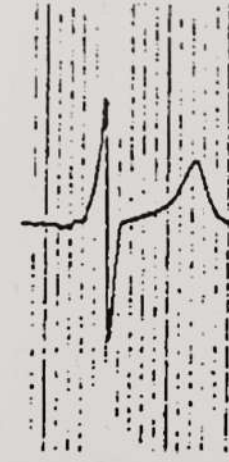

V2

V3

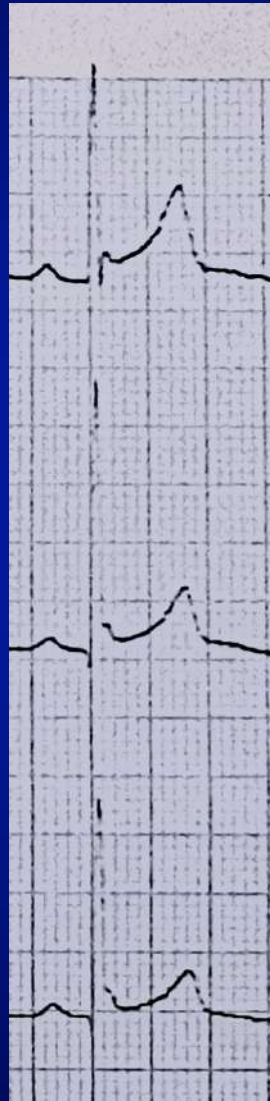
V4

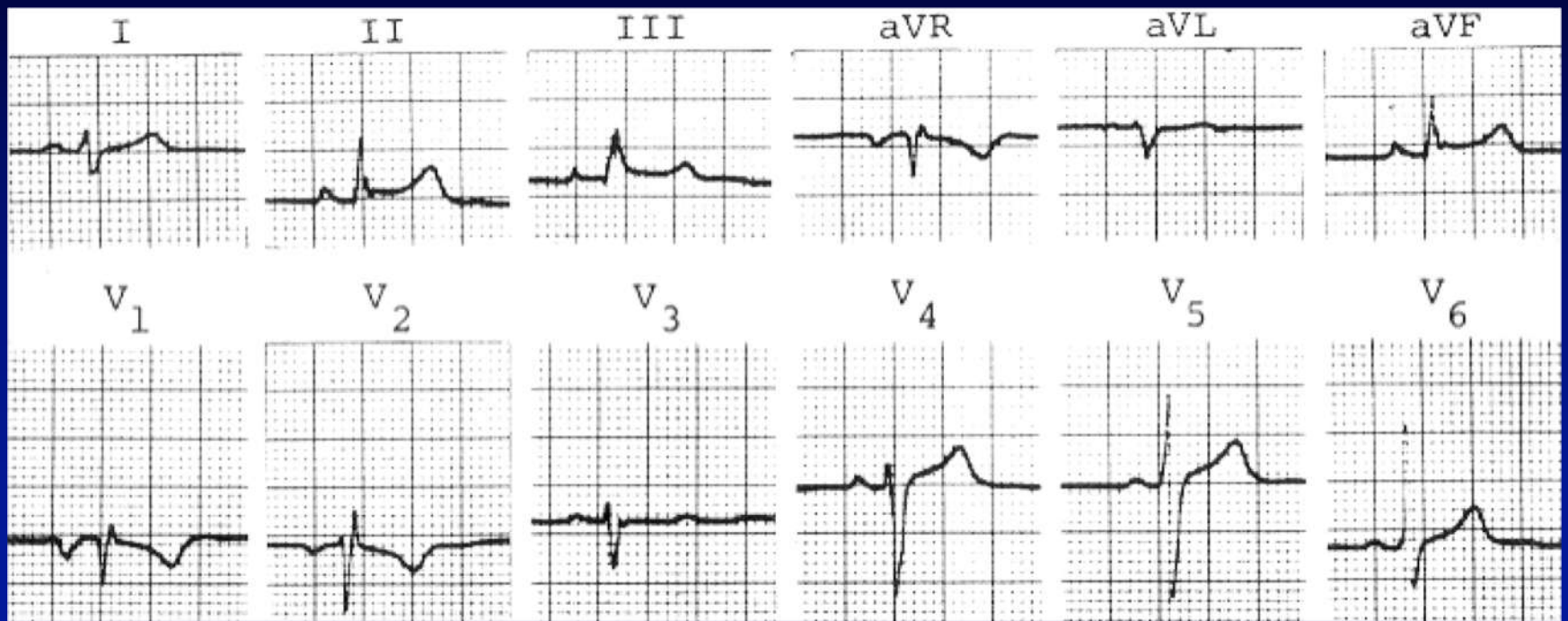
V5

V6



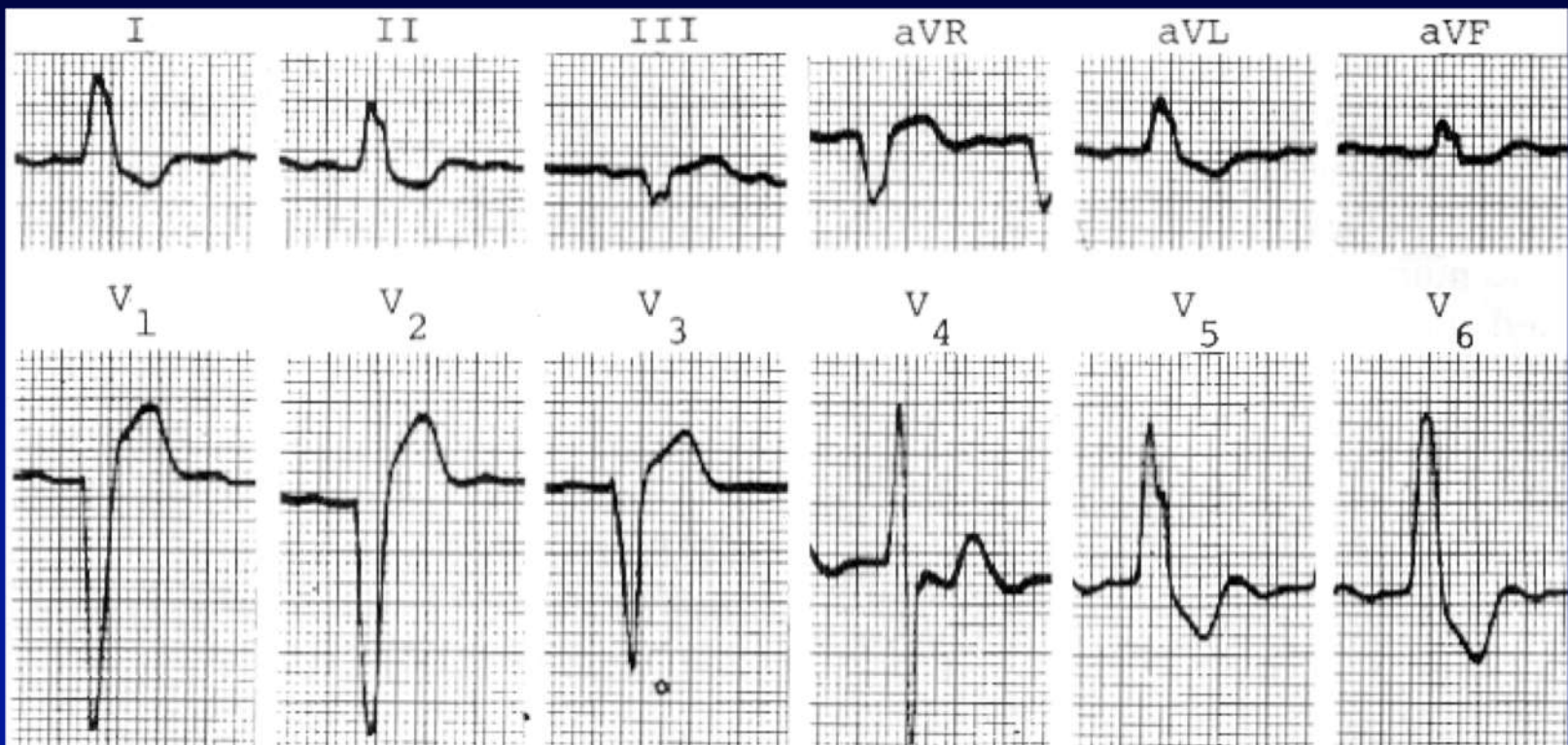
V₄-V₆





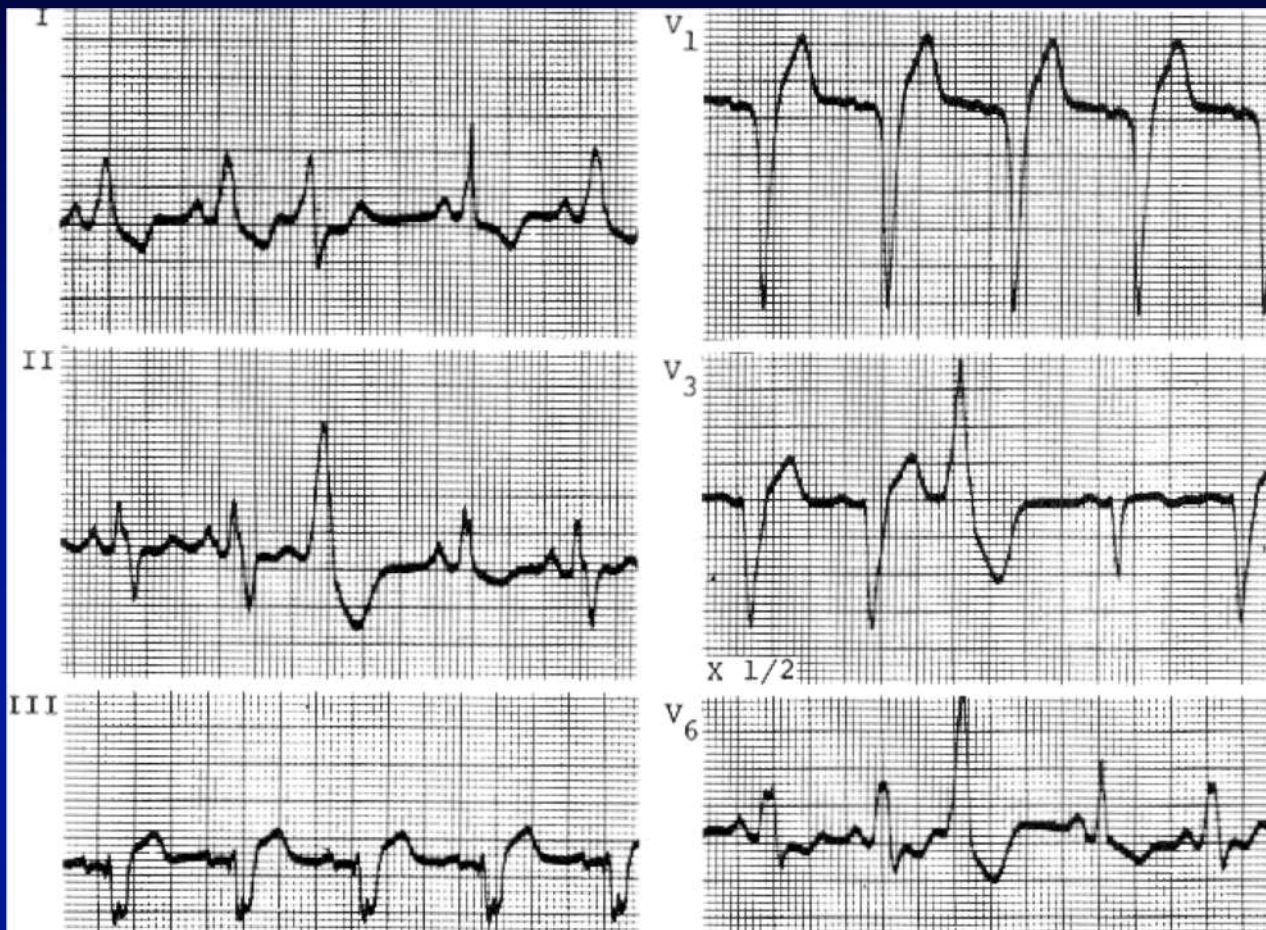
Varón de 21 años, ecocardiograma normal

- 1) Bloqueo incompleto de rama derecha
- 2) Sobrecarga auricular izquierda
- 3) Pectus excavatum
- 4) 1 y 3 pueden ser correctos



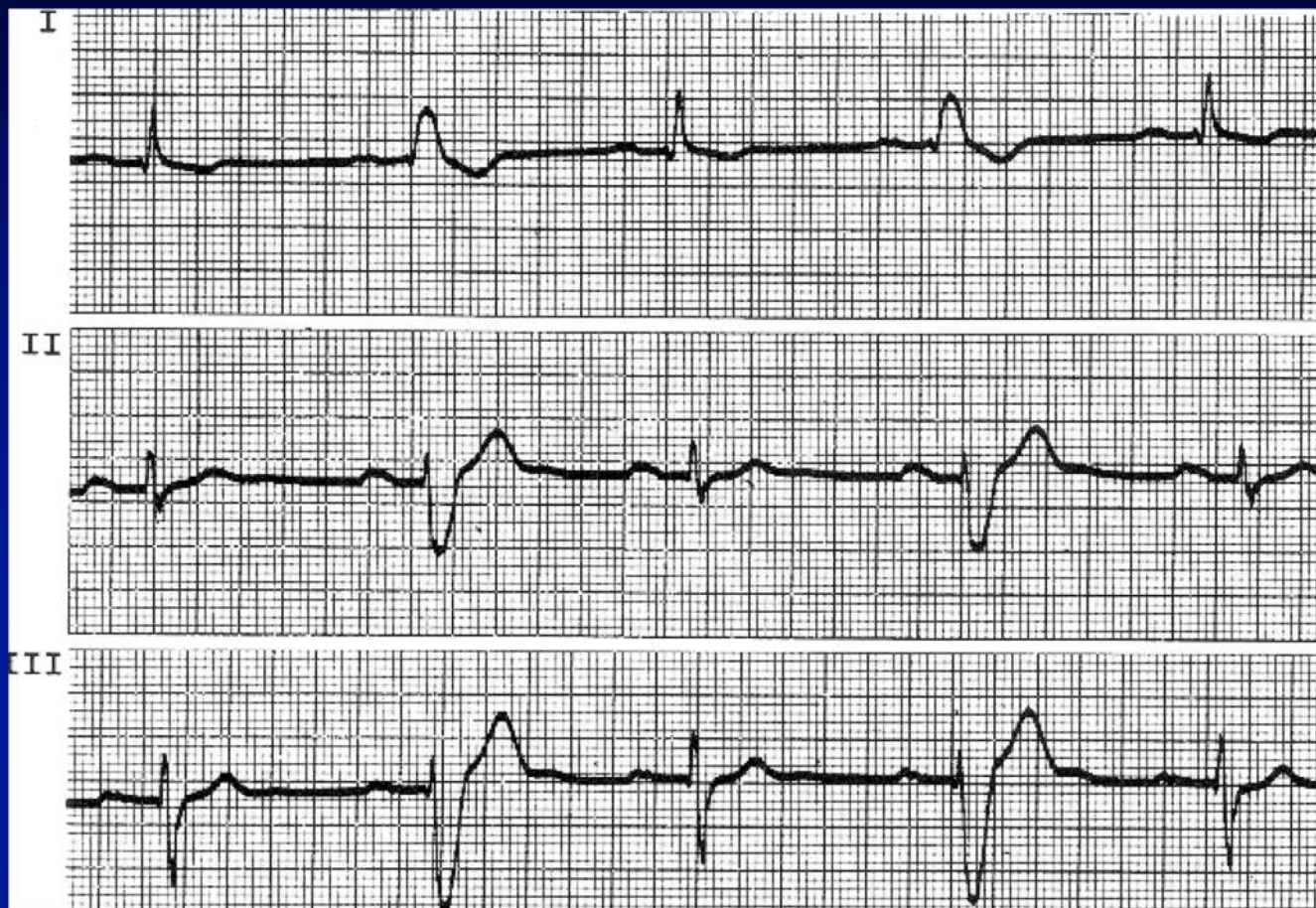
Mujer de 93 años. Calcificación y estenosis severas aórtica y mitral. V₂ y V₃ x 1/2.

- 1) BCRI
- 2) BCRI e hipertrofia ventricular izquierda
- 3) BCRI y secuela anteroseptal

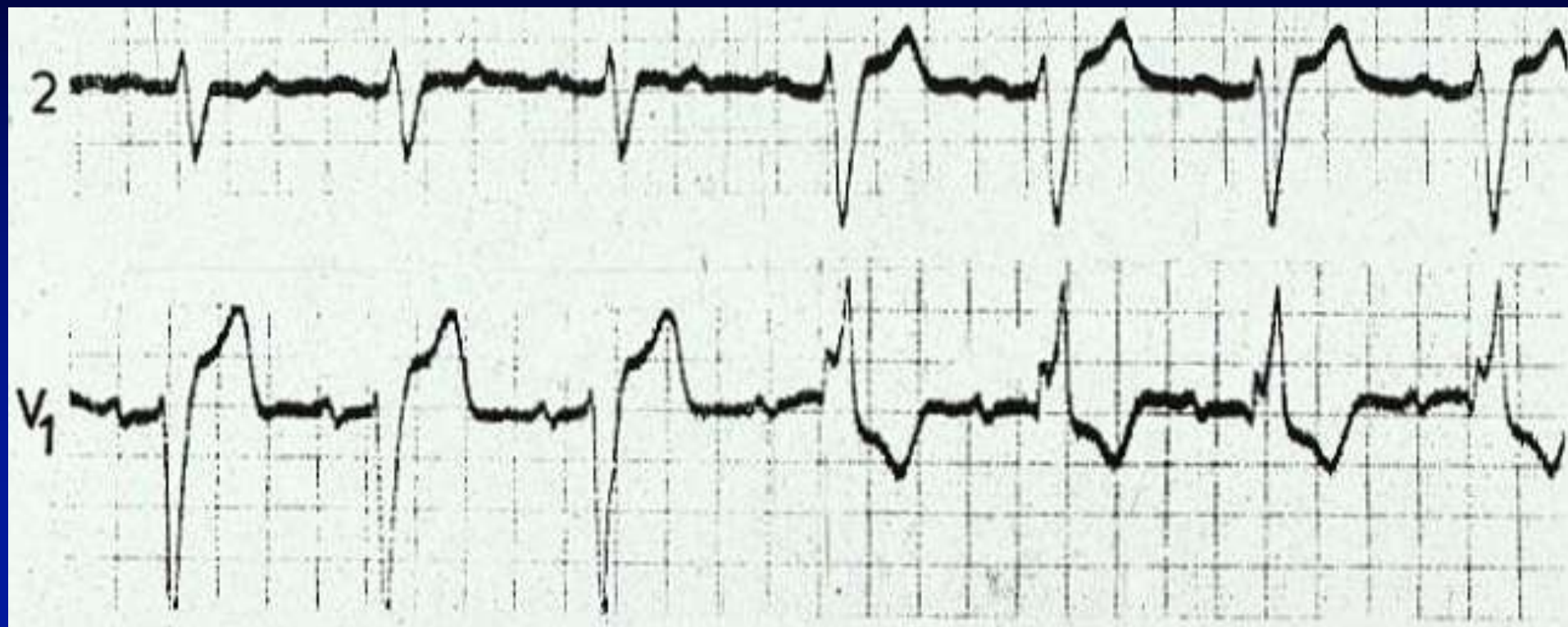


Varón de 55 años, HTA y secuela de infarto apical.

- 1) Extrasistolia ventricular
- 2) BCRI
- 3) Extrasistolia ventricular y BCRI intermitente



- 1) Intervalo PR prolongado
- 2) BCRI intermitente
- 3) Sobrecarga auricular izquierda
- 4) Todas son correctas



- 1) Bloqueo de rama izquierda
- 2) Bloqueo de rama derecha
- 3) Bloqueo de rama alternante
- 4) Bloqueo de rama alternante + hemibloqueo anterior izquierdo